

PATHOLOGICAL AND HISTOLOGICAL CONDITION OF LEG BONES OF TOM TURKEYS GROWN UNDER DIFFERENT ANIMAL DENSITIES

Birgit Spindler, Rita M. Weber*, Jörg Hartung

Institute for Animal Hygiene, Welfare and Behaviour of Farm Animals, Clinic for Poultry
University of Veterinary Medicine Hannover, Foundation, 30559 Hannover, Buenteweg 17p, Germany,*

Key words: outdoor scratching area, joint pathology, pododermatitis

Introduction

Turkey meat consumption in Germany has steadily increased over the years and is currently estimated to be 6.7 kg per capita (2005). In order to keep up with the increasing market special fast weight gaining breeds are used. However, in recent years consumer's concerns with the welfare of these birds and how they are raised have grown, supported by reports about high animal densities with little opportunity to move and explore in the barren environment of enclosed buildings resulting frequently in a poor state of health. Typical pathological findings are changes in joints, bone structure and skin such as arthritis, necrosis and pododermatitis (Hafez 1999). Leg weaknesses seem to be the reason that the animals lie on the ground for longer periods with the consequence of the formation of breast blisters which form the basis for infections with *Staphylococcus spp.* (Bergmann 1992). It is assumed that these animals are suffering from acute and chronic pain. One of the proposed measures to improve the conditions for the animals is to give them access to an outdoor scratching area, also referred to as "Wintergarten". This is an area usually approximately half the size of the ground floor of the building littered with straw or sand, covered by a roof to protect the space from rainfall and surrounded by a strong wire mesh to keep birds and feral animals out. From the sixth week of life the birds have direct access to this area through openings from the animal house. This paper reports on the health condition of male turkeys raised in an animal house with (barn 1) and without (barn 2) access to such a scratching area. Special attention was paid to the pathological condition of the joints, the bone structure and the skin.

Material and methods

Two groups of Big 6 tom turkeys, British United Turkey (B.U.T.) were reared from one- day- old chicks to a final weight of about twenty kg on the experimental farm Ruthe of the University of Veterinary Medicine Hanover. Four fattening periods (P1 to P4) were

observed with a total of 12,000 birds, 6,000 reared in barn 1 (with scratching area) and 6,000 in barn 2 (without scratching area). Feed and water was provided indoors only.

All animals which died between the 6th week of life and the end of the fattening period (585, barn 1: 288, barn 2: 297) were taken for pathological, histo-pathological and bacteriological investigations of leg bones, joints, synovial fluid and skin. A macroscopic evaluation of the joints was performed according to the following scheme:

0	No macroscopical findings (NO)	4	Cartilage lesions (CL)
Different forms of arthritis:			
1	Slight changes of composition and colour of synovial fluid (CD)	5	Haemarthrosis (HA)
2	Moderate changes (MD)	6	Degeneration, necrosis (DC)
3	Severe changes (PD)	7	Articular gout (AG)

Bacteriological investigations of slight to severely altered synovial fluids were carried out of 48 joints (barn 1) and 35 joints (barn 2), respectively. Histological investigations (Paraffin Inbedding, H.-E. staining) were performed from all pathological joints (152 barn 1, 122 barn 2) and from 48 control animals which were clinically inapparent (288 joints). The footpads of all fallen turkeys were investigated on the existence and severity of pododermatitis according to the following assessment scheme:

0	Epithel intact, no findings	2	Moderate hyperceratosis and necrosis, up to 2.0 cm
1	Slight hyperceratosis, coloured epithel area up to 0.5 cm	3	Severe, deep epithel necrosis/hyperceratosis

Results

Casualties: The average losses during the whole 4 fattening periods (P) were at 8.20% (5.57% P 4, 7.10% P3, 7.96% P2 and 12.16% P1) 8.34% (557 birds) in barn 1: and 8.07% (484 birds) in barn 2. In the period between the 6th to the 22nd week the casualties were 4.31% (288 birds) in barn 1 and 4.95% (297 birds) in barn 2, with little differences between the periods.

Joint alterations: Table 1 gives the incidence of alterations in the investigated joints. 1728 joints were investigated of the 288 birds from barn 1 and 1782 joints of the 297 birds from barn 2. 8.80% of the investigated joints from barn 1 and 6.85% joints from barn 2 showed pathological alterations. Pathological alterations of the intertarsal joint dominated in both systems with 18.6% (of 576 intertarsal joints, barn 1) and 14% (of 594 intertarsal joints, barn

2), respectively. 4.5% of the 576 knees showed pathological alterations (barn 1) and 5.6% of 594 knees in barn 2. Alterations of the femur were observed in 3.3% of 576 and 2.0% in 594 investigated bones, respectively.

Figure 1 shows type and frequency of occurrence of all joint alterations in the investigated animals from both barns (barn 1:1728, barn 2: 1782). Synovial alterations occurred

Tab. 1 Incidence of joint alterations

Examined animals (joints)	all joint alterations	alterations articulation intertarsalis	alterations articulation genus	alterations caput ossis femoris
Barn 1 288 (1728)	152 (8.8%)	(n= 576) 107 (18.58%)*	(n= 576) 26 (4.51%)*	(n= 576) 19 (3.30%)*
Barn 2 297 (1782)	122 (6.85%)	(n= 594) 83 (13.97%)*	(n= 594) 27 (5.55%)*	(n= 594) 12 (2.02%)*

*= % from type of joint

predominantly in the intertarsal joints of animals from both barns. In the animal house with scratching area slight (CD) and severe (PD) deviations were distinctly higher than in barn 2. This was also true for cartilage lesions (CL) and articular gout (AG). A few cases of necrosis (DC) were observed in barn 1 none was seen in barn 2. Pathological alterations in the knee joint (articulation genus) were dominated by slight and moderate changes of the synovial fluid. There are only little differences between the barns. The highest incidence of necrosis was found in the femur (caput ossis femoris) of animals from barn 1. Femur changes (AG, DC) of birds from barn 2 were relatively small in number.

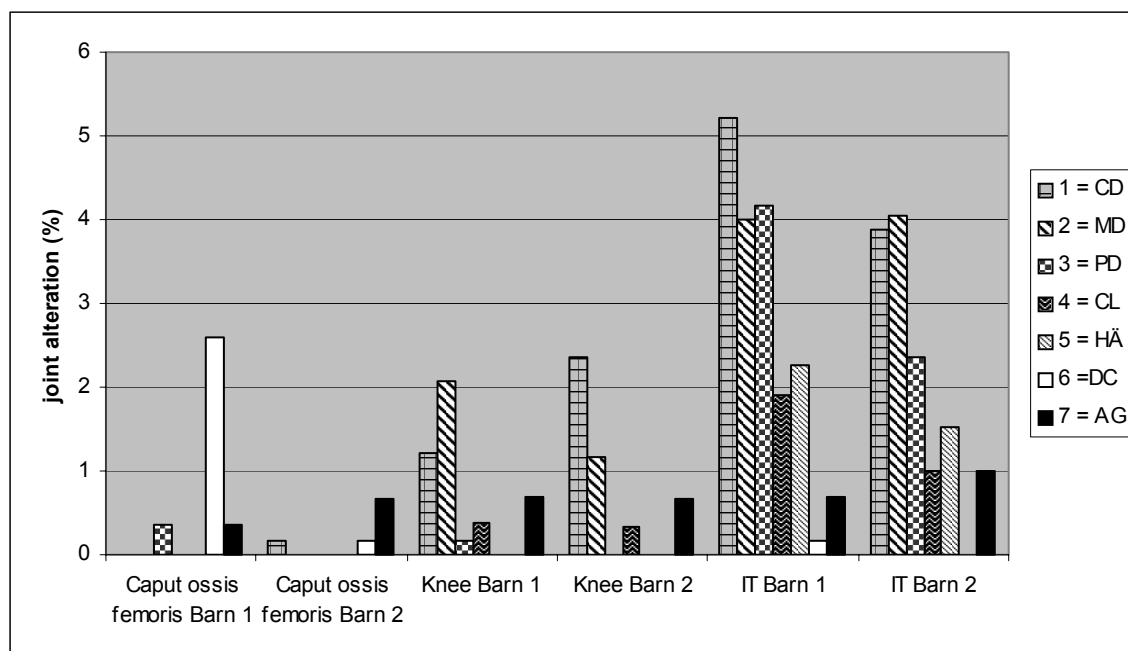


Fig. 1: Type and frequency of occurrence of all joint alterations in the investigated animals from both barns (barn1:n = 1728, barn 2:n = 1782)

75% (36 joints) and 91% (25 joints) of the synovial fluids of the 48 joints from barn 1 and the 35 joints from barn 2 showed bacterial contamination. Most frequently *Staphylococcus* spp., 50% (24 joints) barn 1 and 57% (20 joints) barn 2 was found. *E. coli* was detected in 17% (8 joints) barn 1 and 20% (7 joints) barn 2 of the synovial fluids. 25% (12 joints) of the investigated fluids in barn 1 and 29% (10 joints) in barn 2 gave negativ results. *Mykoplasma* spp. were not found.

Foot pad lesions (Pododermatitis)

Figure 2 shows the frequency (%) and degree of foot pad lesions (pododermatitis) in the investigated animals from both barns. The total number of foot pads showing pododermatitis were slightly higher (not significant, ns) in barn 2 (347 of 594 foot pads, 58%) than in barn 1 (330 of 576 foot pads, 57%). 43% (barn 1) resp. 42% (barn 2) of the investigated foot pads appeared normal (ns) whereas 22% resp. 24% showed slight (ns), 22% resp. 32% moderate (p = 0.05) and 10% resp. 10% severe (ns) hyperkeratosis.

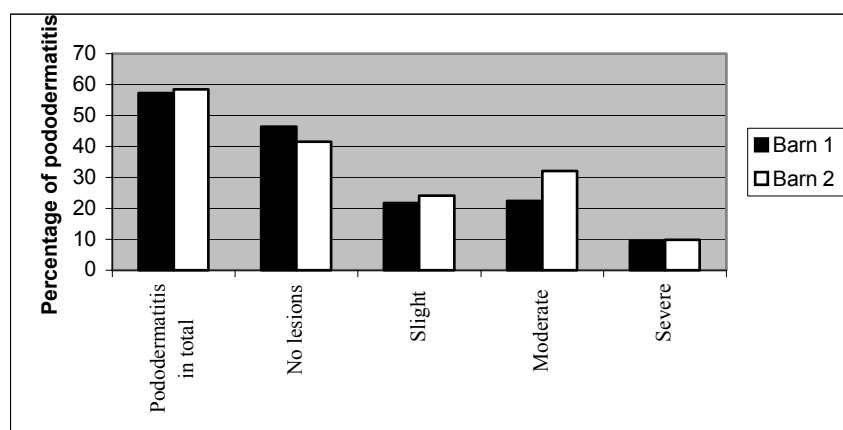


Fig. 2: Frequency and degree (0-3) of pododermatitis in investigated birds from both barns

Discussion and conclusions

The results show that there is a high incidence of different pathological findings in Big 6 tom turkeys kept either under usual housing conditions or with an additional outdoor scratching area. There is a tendency of slightly higher pododermatitis and all types of joint alterations in the barn with the scratching area. However, the number of dead losses in barn 1 was slightly lower than in barn 2 (not significant). It seems that giving the animals simply more space to move around does not significantly influence the incidence and frequency of foot and joint lesions of modern bred tom turkeys for meat production. Management and quality of litter seem also to have an effect on the occurrence of pododermatitis. There is a need for more detailed investigations of the genetical disposition for changes and diseases of leg bones.

Acknowledgements

We thank Mrs. Smyrek for the care of the animals and PD Dr. G. Glünder for the bacteriological analysis.

References

1. *Bergmann, V. (1992): Brustblasen. In: Monreal, G u. G. Heider (Hrsg.): Krankheiten des Wirtschaftsgeflügels. Gustav Fischer Verlag Jena, Stuttgart, Bd. 2, S. 721-723.*
2. *Hafez, H. M. (1999): Gesundheitsstörungen bei Puten im Hinblick auf die tierschutzrelevanten und wirtschaftlichen Gesichtspunkte. Archiv für Geflügelkunde, 63, 73 – 76.*